



# Comprehensive Care of the Gynecologic Oncology Patient

Adrianne Mallen, MD  
Gynecologic Oncologist  
MN Oncology – Minneapolis  
October 3, 2023




1

## Objectives

- Briefly define the **field of gynecologic oncology**.
- Describe preoperative, perioperative and postoperative care of women diagnosed with **endometrial cancer**.
- Discuss preoperative, perioperative and postoperative care of women diagnosed with **ovarian cancer**.
- Characterize preoperative, perioperative and postoperative care of women diagnosed with **cervical cancer**.
- Illustrate preoperative, perioperative and postoperative care of women diagnosed with **vulvovaginal cancer**.
- Outline some common **chemotherapeutic scenarios** in gynecologic malignancies.

2

2

## What is Gynecologic Oncology?

• **Objective #1: Briefly define the field of gynecologic oncology.**

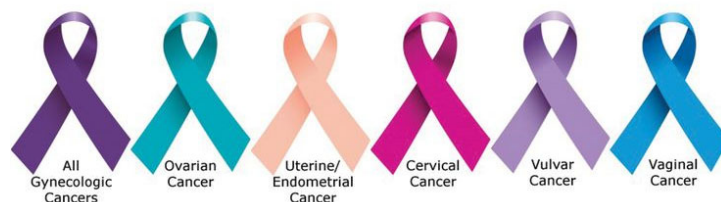- Defined in 1969 as a specialty within obstetrics and gynecology
  - Board certification available in 1973
- 3-4 year fellowship (after 4-year ob/gyn residency)
  - 1-2 years research + 2-year clinical rotations
- Surgical and chemotherapeutic management of women with gynecologic malignancies & precancerous conditions
  - Also complex, non-cancerous surgical management
- Advancement of gynecologic oncologic research
- **Only surgeons that also administer chemotherapy**

Averette HE, Wrennick A, Angioli R. History of gynecologic oncology subspecialty. Surg Clin North Am. 2001 Aug;81(4):747-51. doi: 10.1016/s0039-6109(05)70162-6. PMID: 11551122.

3

3

## Do you know the 5 Gynecologic Cancers?



The Foundation for Women's Cancer wants women to:

**LEARN** the symptoms.

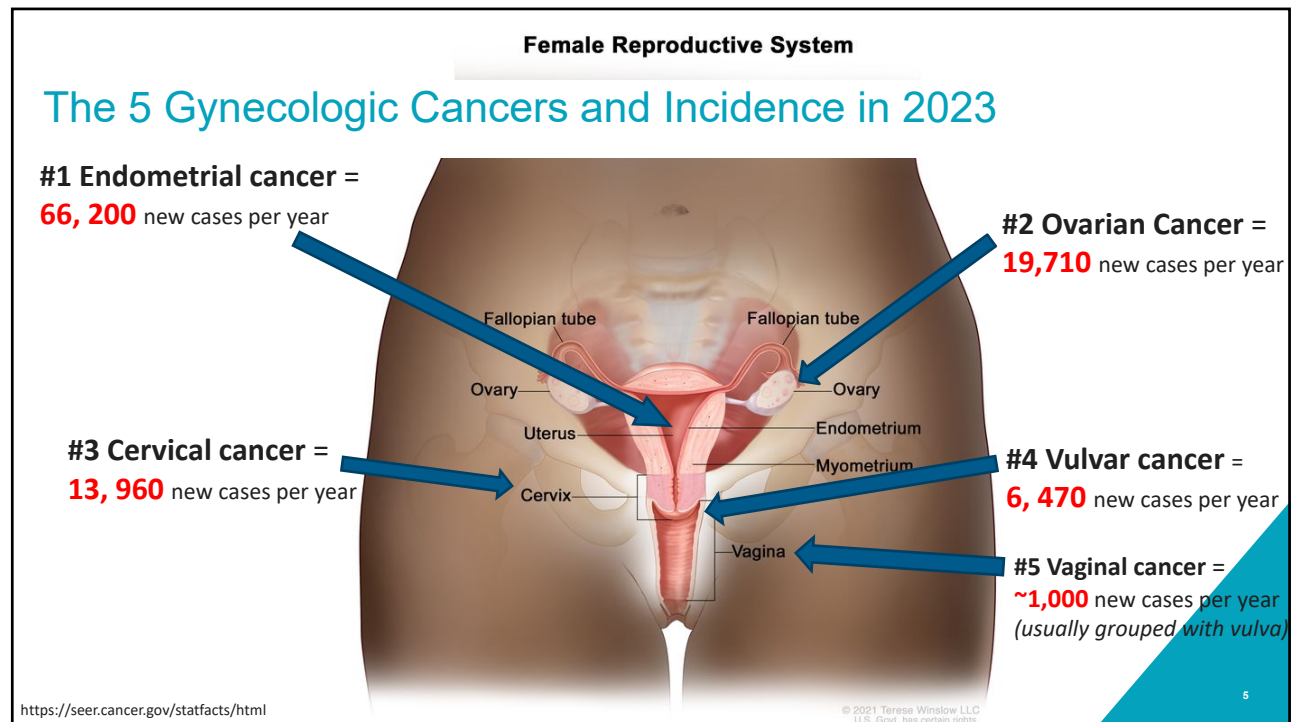
**LISTEN** to your bodies.

**ACT** by seeking care from a gynecologic oncologist if you suspect or have been diagnosed with a GYN cancer.

For more information visit  
[foundationforwomenscancer.org](http://foundationforwomenscancer.org)

4

4

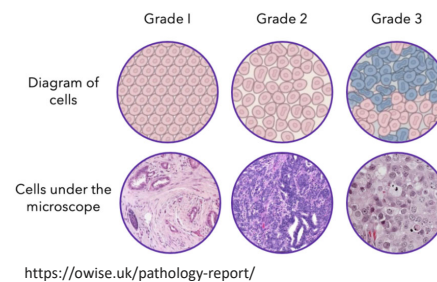


5

## Some Cancer Basics

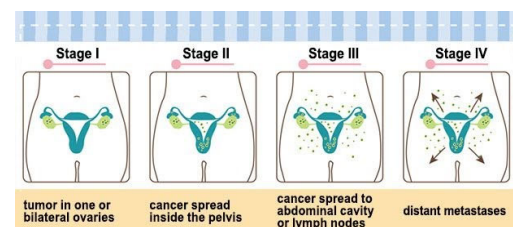
### Grade = APPEARANCE

- Determined by pathology
- Scale of 1-3
  - 1 = well-differentiated (less aggressive)
  - 2 = moderately differentiated
  - 3 = poorly differentiated (more aggressive)



### Stage = LOCATION AND/OR SPREAD

- Determined by imaging and/or surgery
- Scale of 1-4
  - 1 = confined to organ
  - 4 = advanced/metastatic

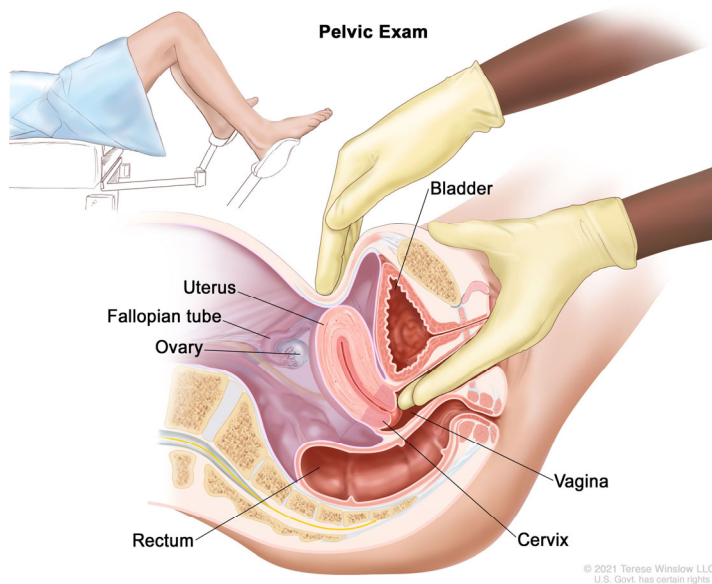


<https://www.facebook.com/SRHRAventures/posts/stages-of-ovarian-cancer-ovarian-cancer-stages-range-from-stage-i-1-through-iv-4/1208399132871334/>

6

6

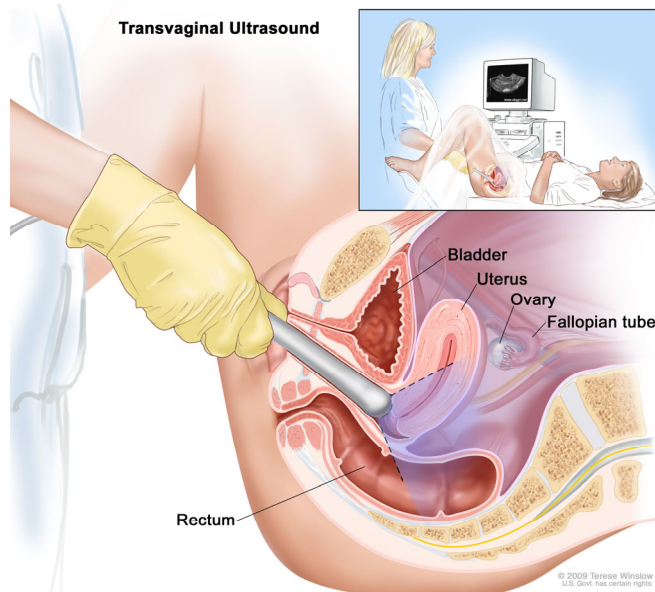
## Gynecologic Examination – Pelvic Examination



<https://nci-media.cancer.gov/pdq/media/images/609924.jpg>

7

## Gynecologic Evaluation – Transvaginal Ultrasound



<https://www.cancer.gov/types/uterine/patient/endometrial-screening-pdq>

8

## Endometrial Cancer

• **Objective #2:** Describe preoperative, perioperative and postoperative care of women diagnosed with **endometrial cancer**.

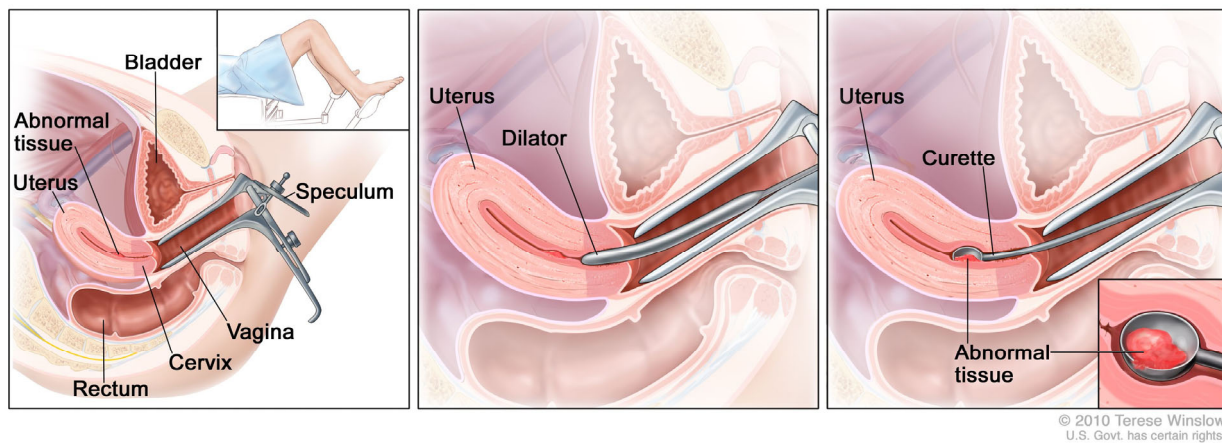
- Most **common** gynecologic malignancy in US
- Clinical presentation: abnormal uterine bleeding (75-90%)
- Diagnosis: Biopsy
- Treatment: Surgery (usually)
- Age: 60
- Stage: usually early
- Prognosis: 5 year OS for stage 1 = 80-90%

10

10

## Gynecologic Evaluation – Dilation & Curettage

### Dilatation and Curettage



<https://nci-media.cancer.gov/pdq/media/images/680398.jpg>

11

11

## Endometrial Cancer Staging

Stage	Description
IA	Tumor confined to uterus, <50% myometrial invasion
IB	Tumor confined to uterus, ≥50% myometrial invasion
II	Cervical stromal invasion
IIIA	Tumor invasion into serosa or adnexa
IIIB	Vaginal or parametrial involvement
IIIC1	Pelvic node involvement
IIIC2	Paraortic node involvement
IVA	Tumor invasion into bladder or bowel mucosa
IVB	Distant metastases (including abdominal metastases) or inguinal lymph node involvement

12

12

## Endometrial Cancer – Case #1

A 65 yo presented to gynecology visit for postmenopausal bleeding x 1 month. An endometrial biopsy was performed and revealed endometrial adenocarcinoma, grade 3. She was referred to gynecologic oncology clinic. A CT scan of chest/abdomen/pelvis showed no evidence of metastatic disease. Surgery was discussed with her and she elected for robotic surgery with staging.

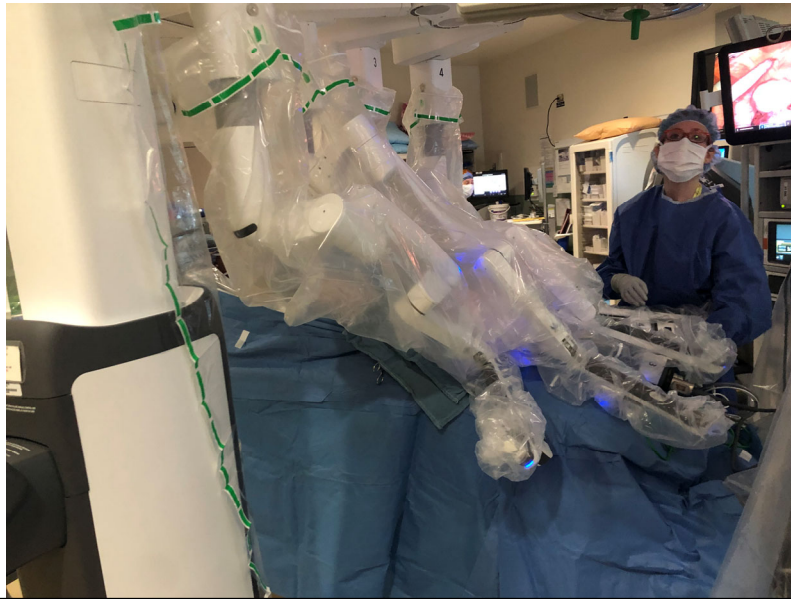
DaVinci Xi robot

13

13



## Endometrial Cancer – Case #1 - Robotic Surgery



**DaVinci XI robot  
docked with 4  
ports & assistant  
port. First assist  
pictured with Gyn  
Onc PA-C.**

14

14