

Case Presentation

Katie Freeman, MD
Allina Health Orthopedics
Allina Health Sports Medicine Conference
August 5, 2022



1

HPI

- 28yo F presented with 2 years of right hip pain
- Tried physical therapy and NSAIDs without improvement
- Had a greater trochanter bursal injection about 2 years ago which helped
- Complained of pain in the anterior hip/groin, buttock, lateral hip
- Pain with prolonged sitting, standing, walking

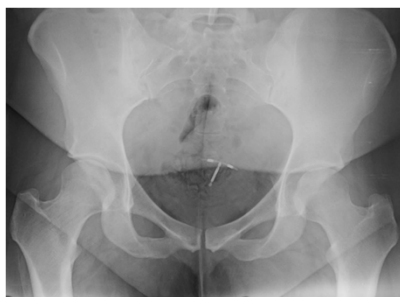2

Physical Exam

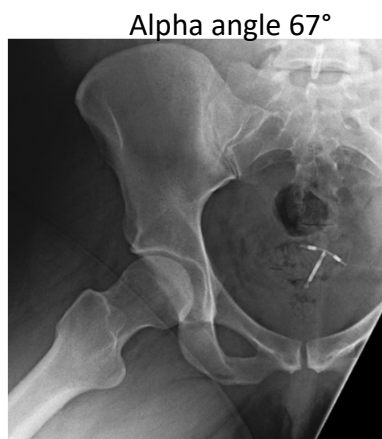- ROM
 - 90° flexion, 50 ° ER, 30 ° IR
- (+) FADIR, (+) Butterfly, (-) posterior impingement
- (+) log roll
- Pain with SLR
- Pain with resisted hip flexion
- Mild pain with 5/5 strength hip abduction

3

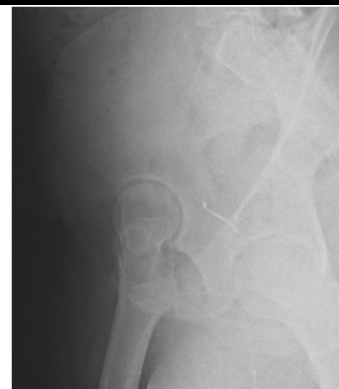Imaging



LCE angle 30°

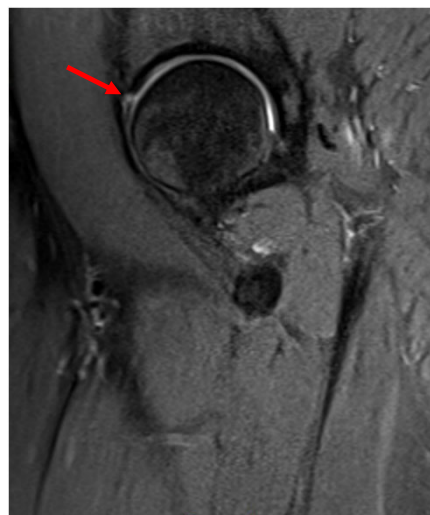
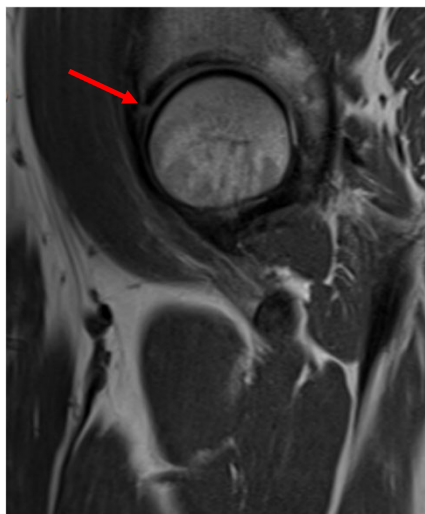


Alpha angle 67°



4

Imaging

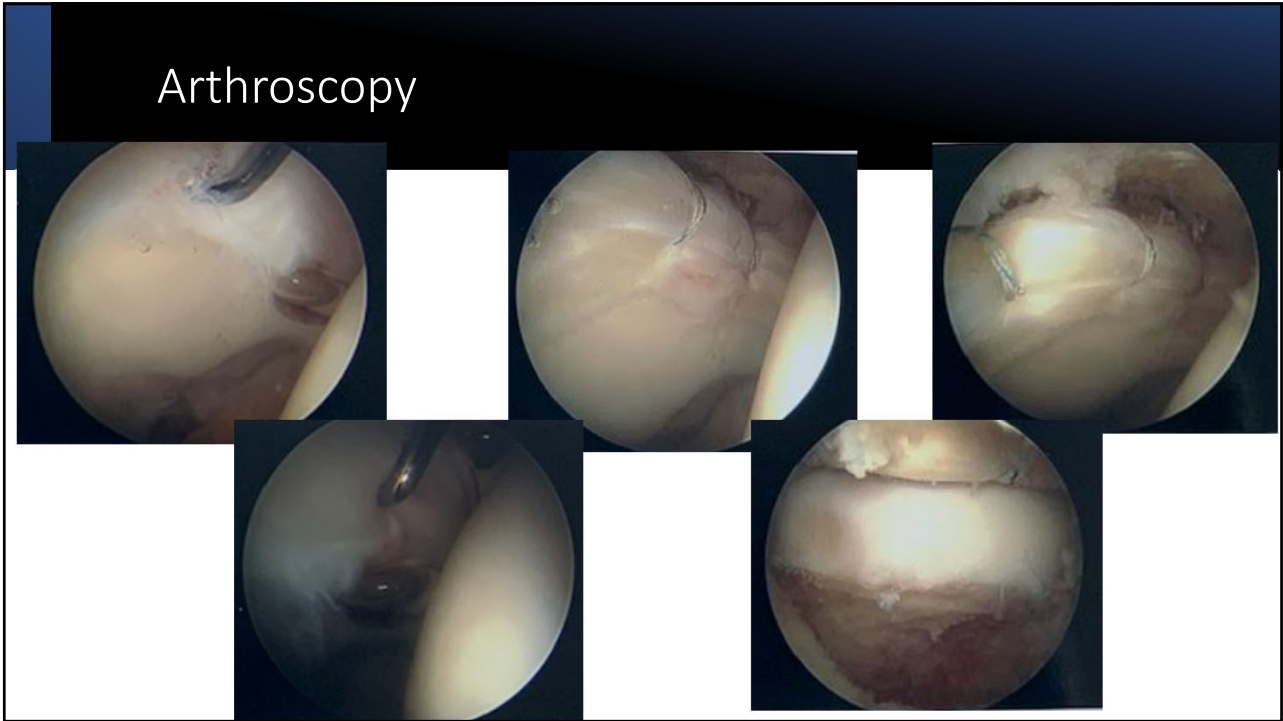


5

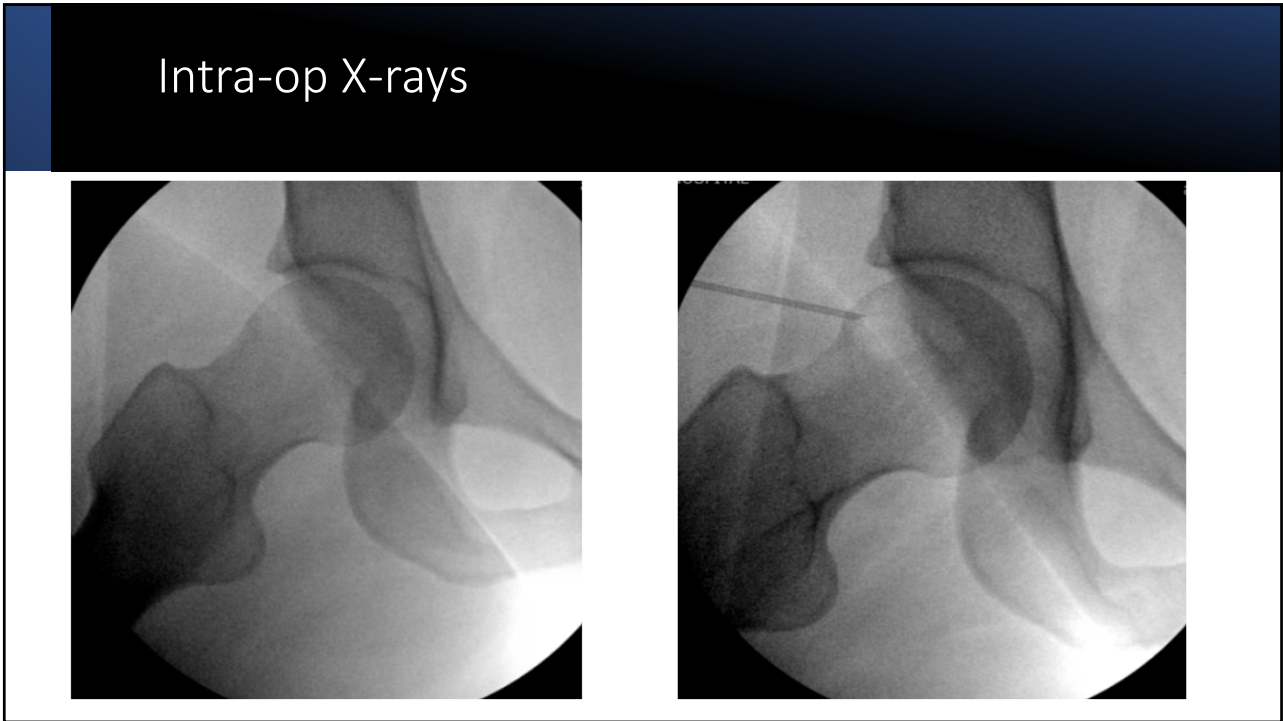
Diagnostic Injection

- Recommended diagnostic injection because of more diffuse symptoms
- Had **75% relief of symptoms** with injection
- Exam after injection
 - **(-) FADIR**
 - **(-) Butterfly**
 - No pain with SLR

6



7



8

Questions?

9