

## DIFFICULT PATIENTS: CHALLENGES AND CHOICES

Louise C. Miller, RTRM, CRT, FSBI, FNCBC  
Director of Educator: Mammography Educators LLC

February 29, 2020

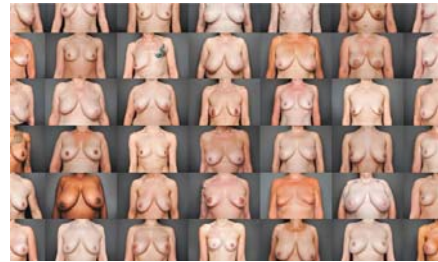

## OBJECTIVES

- Identify specific challenging patient populations
- List methods for documentation of patient conditions
- Discuss options for additional views

## Challenging Patients

- Challenges with patient circumstances
- Challenges with body habitus issues
- Patients with challenging personalities



## Positioning Dilemmas of Mammography

- Unique patient circumstances
- Patient limitations
- Body habitus issues

## Positioning Dilemmas of Mammography

- **Unique patient circumstances**
  - Wheelchairs
  - Gurneys
  - Scooters
  - Pacemakers, portacaths, defibrillators, shunts



### Try something different

- Do the opposite

Instead of the CC do the FB

Instead of the MLO do LM

### Positioning Dilemmas of Mammography

#### - Patient limitations

#### Special needs:

- Can't stand unassisted
- Limited ROM – neck, shoulder, arm etc.
- Partial or full paralysis
- Overly medicated
- Developmentally disabled
- Elderly, Infirm
- Confused



### Can't stand unassisted

Do her seated in a chair or if confined to a wheelchair  
remove the arms if possible

### Limited ROM Full or Partial Paralysis

- Mostly does not affect CC
- If you can't do a MLO...do a LM or ML
- For visualization of UOQ do slightly angled AT

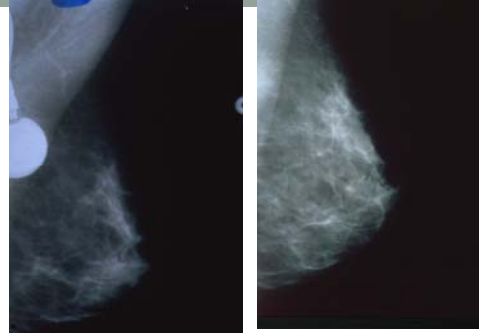
### Positioning Dilemmas of Mammography

Patient limitations

Special needs:

- Overly medicated
- Developmentally disabled
- Elderly, Infirm
- Confused

- Override automatic compression release
- Let them hang on
- Get assistance



### Don't just ask: "Can you stand?"

Mammography requires:

- \* Balance
- \* Stability
- \* ROM

Ask them if they do things in their "real life" that require similar ability: i.e. "Do you get to and from the bathroom on your own?"

### When in doubt.....

- Don't push it!
- Document, document, document

### Any and all – single or combo

- Can't stand unassisted
- Limited ROM – neck, shoulder, arm etc.
- Overly medicated
- Developmentally disabled
- Partial or full paralysis

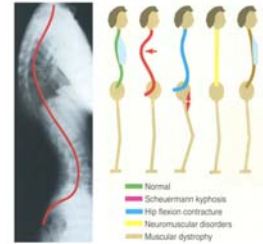
DO YOUR BEST.....

## Positioning Dilemmas of Mammography

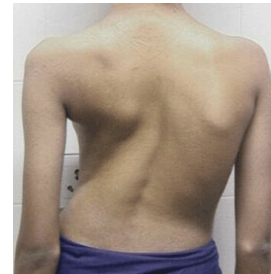
### • Body habitus issues

- Kyphosis
- Scoliosis
- Pectus carinatum
- Pectus excavatum
- Prominent abdomen
- Thick axilla

## Kyphosis



## Scoliosis



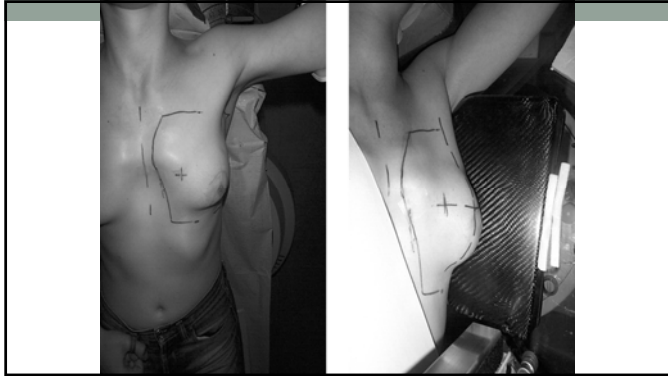
## Scoliosis

Two different degrees of angulation for the MLOs can be used as each side of the thorax is different. i.e. 45 degrees on LMLO and 50 degrees on the RMLO

## Positioning Dilemmas of Mammography

### • Body habitus issues

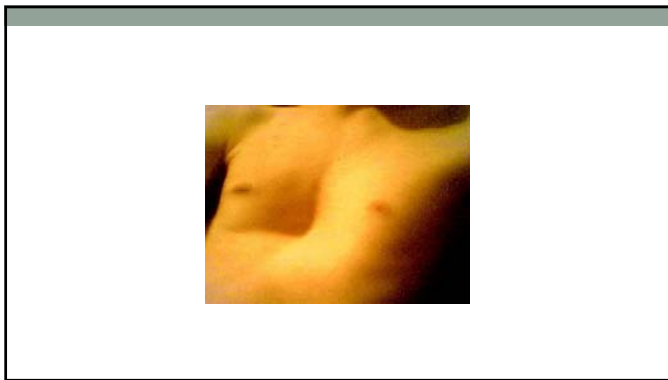
**Pectus carinatum**, also called **pigeon chest**, is a deformity of the chest characterized by a protrusion of the sternum and ribs.



## Positioning Dilemmas of Mammography

### Body habitus issues

**Pectus excavatum** (a Latin term meaning *hollowed chest*) is the most common congenital deformity of the anterior wall of the chest, in which several ribs and the sternum grow abnormally. This produces a caved-in or sunken appearance of the chest. It is usually present at birth and progresses during the time of rapid bone growth in the early teenage years, but in rare cases does not appear until the onset of puberty.



## Again....Try something different

- Do the opposite

Instead of the CC do a "lordotic" CC

Instead of the MLO or LM

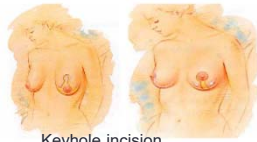## Recommendations:

- Try to do the standard views first to show the radiologist that an attempt was made
- Add views as needed to image as much breast tissue as possible
- Document, document, document

## Breast Reduction, Augmentation or Reconstruction

- Mammographic changes after the above procedures very common
- Variety of techniques utilized in breast reduction
  - Most common is keyhole incision

## Breast Reduction - Mammoplasty



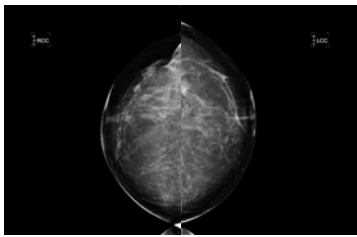
Keyhole incision

## Breast Reduction

Typical mammographic findings include:

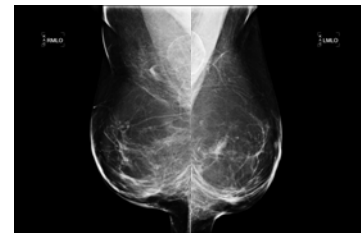
- Alteration of parenchymal architecture
- Cranial displacement of nipple
- Patchy densities due to tissue removal & scarring
- Development of fat necrosis
- Shortening of the pectoralis muscle: *Use 35 degrees for MLO*
- Establish new baseline 6 months after surgery

## Breast Reduction



CCs demonstrating disruption of normal pattern

## Breast Reduction



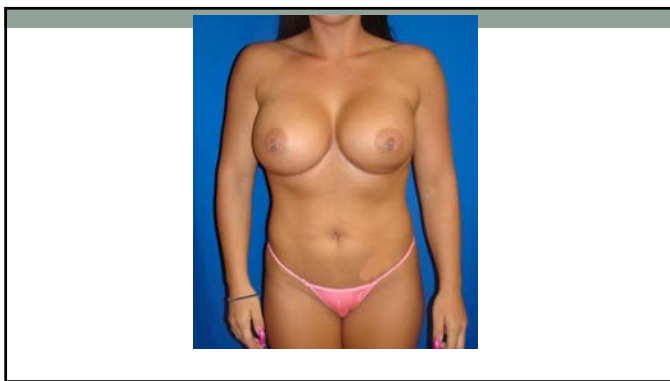
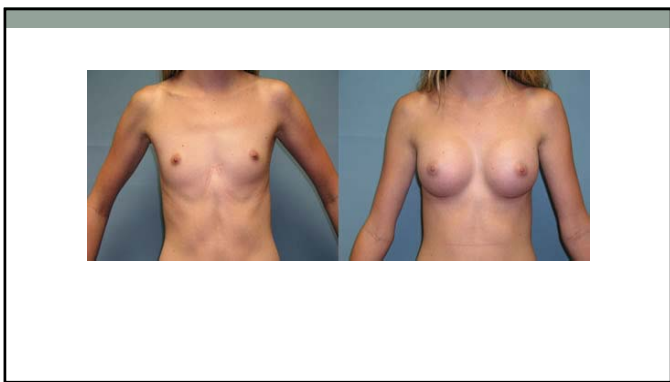
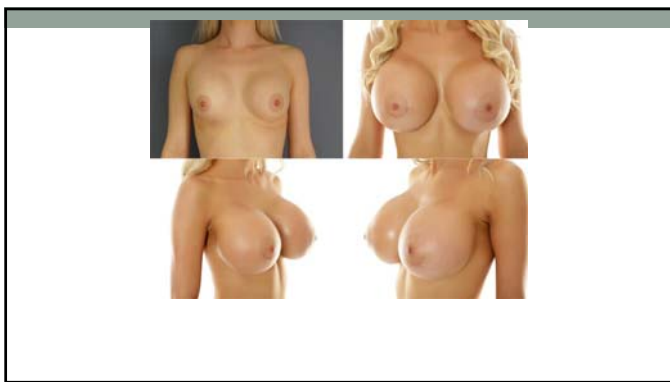
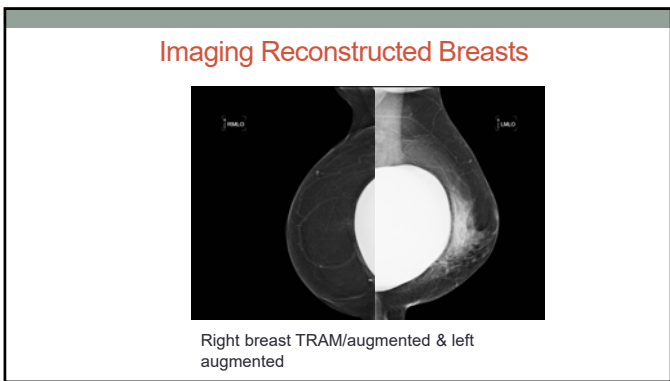
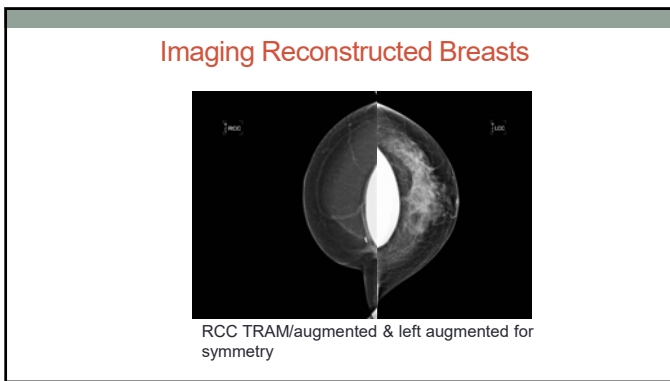
MLO views post reduction

## Breast Reconstruction

- Performed after mastectomy by means of reconstruction with autogenous tissue transfer &/or implants
- Most common location of donor tissue is a flap harvested from transverse rectus abdominus muscle (TRAM) flap or latissimus dorsi

## Flap Reconstruction

- Standard mammographic views performed along with additional views as needed (CC & MLOs)
- Most mammographic & clinical findings are related to development of dystrophic changes within donor tissue such as oil cysts & fat necrosis



- ### Imaging Augmented Breasts
- As suggested by the ACR/CAR, 4 views of each breast should be performed to include:
    - Standard and Implant Displaced views
  - Assessment of the Implant includes:
    - Location: subglandular or subpectoral
    - Type: Silicone, Saline or Mixed
    - Contour: Evaluate for rupture, weakening & possible complications such as rupture/capsular formation

### Remember!!

Full implant views are done for posterior breast tissue.

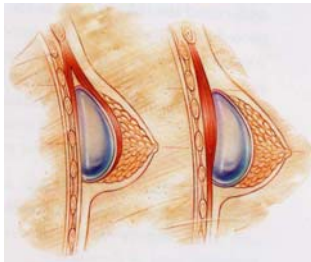
- On the full CC show deep posterior medial and lateral breast tissue (i.e. cleavage)
- The full MLO should visualize deep posterior breast (i.e. axilla and IMF)
- Compression should be applied just enough to immobilize the implant and prevent motion unsharpness

### Remember!!

ID views are done to visualize anterior breast tissue.

- The CCID is done to show deep anterior breast tissue
- The MLOID should visualize anterior breast
- It is rare to see the IMF on the ID views
- Taut compression may be applied

### Imaging Augmented Breasts

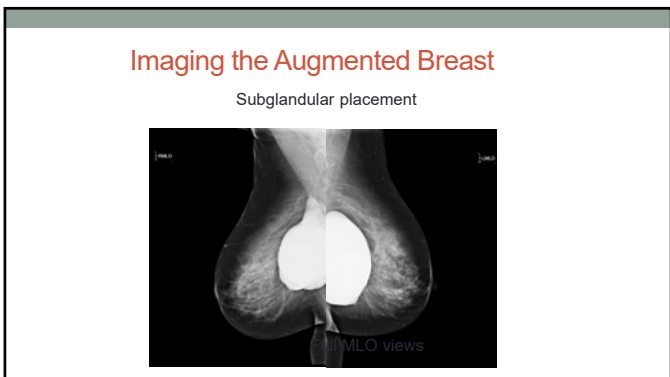
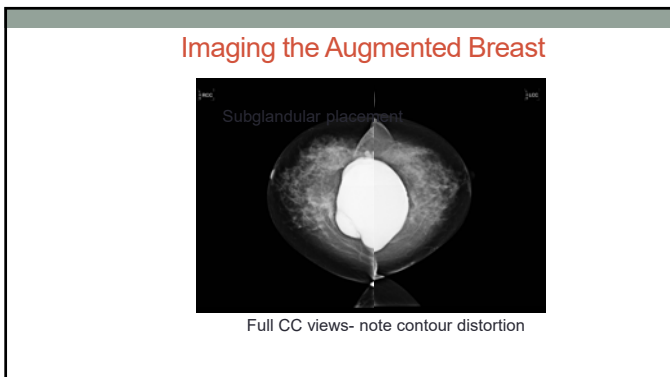
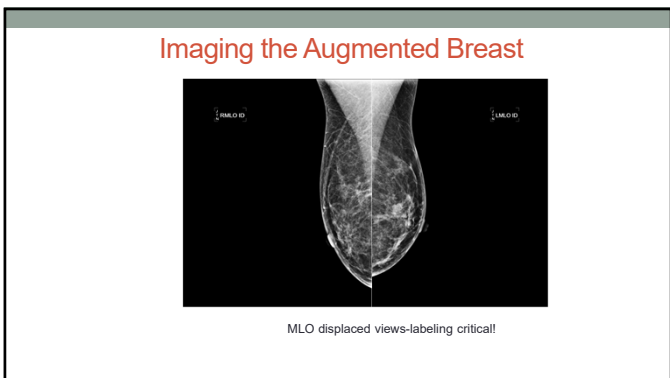
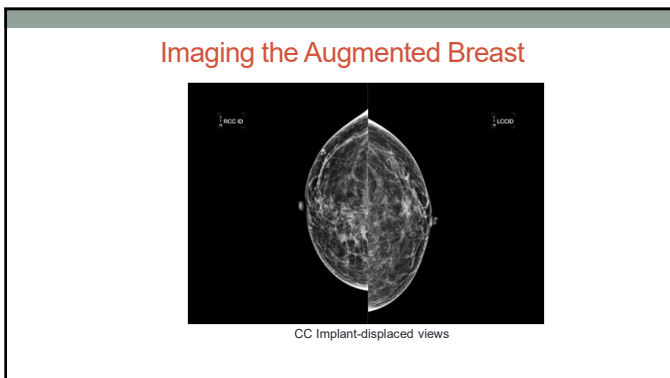
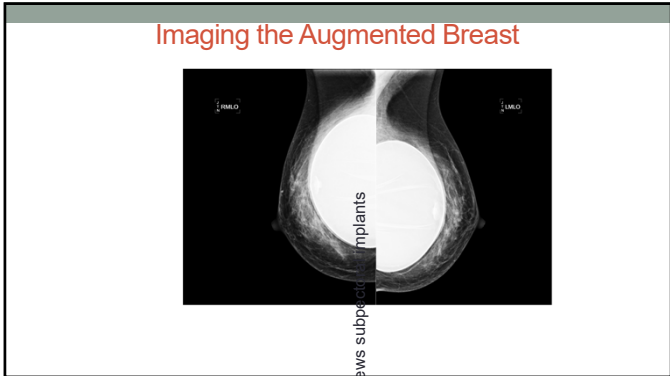
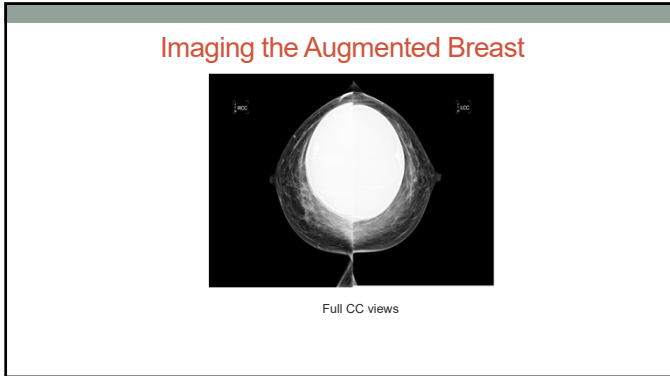


Sub-pectoral      Sub-glandular placement

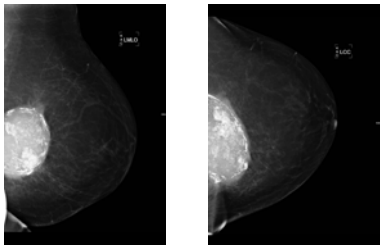
### Suggestions for Implants

- Use only minimal compression on the full Implant views to prevent motion unsharpness
- Sit the patient down for the ID views
- Stand behind the patient
- Pull forward rather than push back



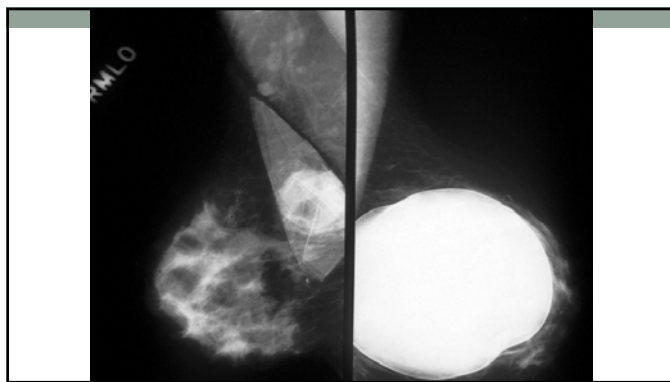


### Miscellaneous Findings



Post implant removal with calcified capsule

### Totally encapsulated implants



### Patient with Challenging Personalities

- "IS THIS ALL YOU DO ALL DAY LONG?"  
*Suggested response:* Actually I really like my job because I know it makes a difference in people's lives. Thanks for asking. ;-)
- "IF I DIDN'T HAVE CANCER BEFORE I'M SURE I'LL GET IT NOW"  
*Suggested response:* Actually mammography is the most highly scrutinized of all xray exams so you can be sure that the compression and exposure are very safe and does not cause cancer.

### Patient with Challenging Personalities

- THE PATIENT TRIES TO POSITION HERSELF:  
*Suggested response:* "Thank you for wanting to help but this will go a lot quicker if I can position you, that's my job. Your job is to relax as best you can and let me know if the compression gets beyond the point of being uncomfortable."

### Patient with Challenging Personalities

- THE PATIENT WILL NOT TOLERATE ADEQUATE COMPRESSION:  
*Suggested response:* I understand that this is not a comfortable exam...and it is not supposed to be painful. But compression is a very important part of getting a good mammogram. So why don't we try again and this time I will use the hand control (vs foot) so the compression will come down very slowly.

### Patient with Challenging Personalities

NOTE: If the patient will not allow adequate compression try to work with her and let her compress herself with the foot paddle. Studies show that patients compress themselves 30% more than a tech needs to compress.

Well, what's that all about? Control.

### Patient with Challenging Personalities

#### • PATIENT IS RUDE OR CONDESCENDING

*Suggested response:* Mrs. Smith, I appreciate that this is not a comfortable exam and it seems like you and I are not working well together as your comments are so negative. I am a medical professional trying to do what is required of me to get a good mammogram which benefits you. Would you like me to ask another technologist to step in and complete your exam.

### Patient with Challenging Personalities

• NOTE: This is NOT about you so don't take it personally. Usually the situation may "turn around" quickly if you point this out to them.